



Spontaneous Resolution of Inguinal Hernias and the Role of Gut-related Secretomotor Disorders *via* the PNEI Axis in Early vs Late Inguinal Hernia Repair in Preterm Infants

More AB¹, Khatri LK², Zaparackaite P, Singh SJ⁴, Swamy KB⁵, Mehta AR⁶, Midha PK⁶ and Patel RV^{7*}

¹Department of Pediatric Surgery, Southampton General Hospital, UK

²Pediatric Emergency Department, Shree Swaminarayan Vishwa Mangal Gurukul PSM Hospital, Ahmedabad, India

³Department of Pediatric Surgery, Evelina Children's Hospital, London, UK

⁴Department of Pediatric Surgery, Nottingham University Hospitals, Nottingham, UK

⁵Lincoln Uni College, 2, Jalan Stadium, 47301 Petaling Jaya, Selangor, Malaysia

⁶J. Watumull Global Hospital & Research Centre, Delwara Road, Mount Abu, Rajasthan, India

⁷Department of Pediatric Surgery, PGICHR and KTCGUH, Rajkot, Gujarat, India



WebLog Open Access Publications

Article ID : wjp.2026.f0605
Author : Dr. Ramnik Patel, MD

OPEN ACCESS

*Correspondence:

Dr. Ramnik Patel, MD, Department of Pediatrics and Pediatric Surgery, Postgraduate Institute of Child Health & Research and KT Children Govt University Teaching Hospital, Rajkot 360001, Gujarat, India, Tel: +447956896641;

E-mail: ramnik@doctors.org.uk/ ORCID: <https://orcid.org/0000-0003-1874-1715>

Received Date: 02 May 2026

Accepted Date: 04 Jun 2026

Published Date: 06 Jun 2026

Citation:

More AB, Khatri LK, Zaparackaite I, Singh SJ, Swamy KB, Mehta AR, et al. Spontaneous Resolution of Inguinal Hernias and the Role of Gut-related Secretomotor Disorders *via* the PNEI Axis in Early vs Late Inguinal Hernia Repair in Preterm Infants. *WebLog J Pediatr*. wjp.2026.f0605. <https://doi.org/10.5281/zenodo.20907240>

Copyright © 2026 Dr. Ramnik Patel. This is an open access article distributed under the Creative Commons Attribution License, which permits unrestricted use, distribution, and reproduction in any medium, provided the original work is properly cited.

Abstract

Inguinal hernia remains one of the most frequent surgical conditions in preterm infants. While early repair has traditionally been advocated to prevent incarceration, emerging evidence suggests that delayed intervention may allow for spontaneous resolution in select cases. This review synthesizes updated systematic reviews and meta-analyses, incorporating Trial Sequential Analysis (TSA), to evaluate the balance between early versus late repair. Particular attention is given to the role of gut-related secretomotor disorders mediated through the Psycho-Neuro-Endocrine-Immune (PNEI) axis, which may underpin spontaneous regression of hernias in preterm infants.

Summary Box

What is already known on this topic

- Inguinal hernia is common in preterm infants, with incidence inversely related to gestational age.
- Early surgical repair has traditionally been recommended to prevent incarceration, despite anesthesia-related risks.
- Reports of spontaneous resolution in delayed repair cohorts have been documented but remain underexplored mechanistically.

What this study adds

- Updated systematic review and trial sequential analysis show that evidence is insufficient to mandate universal early repair.
- Spontaneous resolution occurs in a subset of infants when repair is delayed beyond 55 weeks corrected age.
- A novel mechanistic framework is proposed: gut secretomotor disorders mediated via the Psycho-Neuro-Endocrine-Immune (PNEI) axis may explain both hernia persistence and regression.

How this study might affect research, practice or policy

- Supports individualized timing of hernia repair in preterm infants, balancing risks of incarceration against potential spontaneous resolution.
- Encourages integration of developmental physiology and systems medicine (PNEI axis) into surgical decision-making.
- Highlights the need for future trials incorporating motility biomarkers and neuroendocrine profiling to refine patient selection and optimize outcomes.

Introduction

Inguinal hernia occurs in up to 30% of preterm infants, with risk inversely proportional to gestational age. Conventional surgical dogma favors early repair to prevent incarceration, yet recent studies highlight risks of anesthesia-related complications and recurrence in fragile neonates. Spontaneous resolution, though historically underappreciated, has been documented in delayed repair cohorts. The PNEI axis - integrating gut motility, neuroendocrine signalling, and immune modulation - offers a novel mechanistic framework for understanding spontaneous regression. This work is nested within an updated systematic review and meta-analysis comparing early versus late inguinal hernia repair in preterm infants, incorporating trial sequential analysis to assess the strength and sufficiency of current evidence.

Methods

- Updated systematic review of randomized controlled trials (RCTs), cohort studies, and meta-analyses published over the last decade.
- Trial Sequential Analysis (TSA) applied to assess cumulative evidence strength and reduce risk of type I error.
- Outcomes Included spontaneous resolution rates, incarceration incidence, recurrence, perioperative complications, neurodevelopmental outcomes.

Results

Early vs Late Repair

- **Early repair:** Lower risk of incarceration but higher rates of postoperative apnea and anesthetic complications.
- **Late repair:** Reduced perioperative risk, with documented spontaneous resolution in a subset of infants beyond 55 weeks corrected gestational age.
- TSA indicates that current evidence is insufficient to mandate universal early repair, supporting individualized decision-making.

The pooled meta-analysis demonstrated that early repair reduced the risk of incarceration (RR 0.55, 95% CI 0.40-0.75), while late repair increased the likelihood of spontaneous resolution (RR 2.10, 95% CI 1.30-3.40). As shown in Figure 1, trial sequential analysis boundaries indicate that current evidence remains insufficient to mandate universal early repair, supporting individualized decision-making based on clinical context.

As illustrated in Figure 2, spontaneous regression of inguinal hernia was observed in a subset of infants beyond 55 weeks corrected gestational age. The conceptual model highlights the role of gut secretomotor maturation and PNEI axis stabilization in facilitating hernia resolution. As illustrated in Figure 2, this phenomenon may be mediated by maturation of gut secretomotor function and stabilization of the Psycho-Neuro-Endocrine-Immune (PNEI) axis, which collectively reduce intra-abdominal pressure and facilitate hernia resolution.

Spontaneous Resolution

- Observed in 10-15% of preterm infants when repair is delayed.

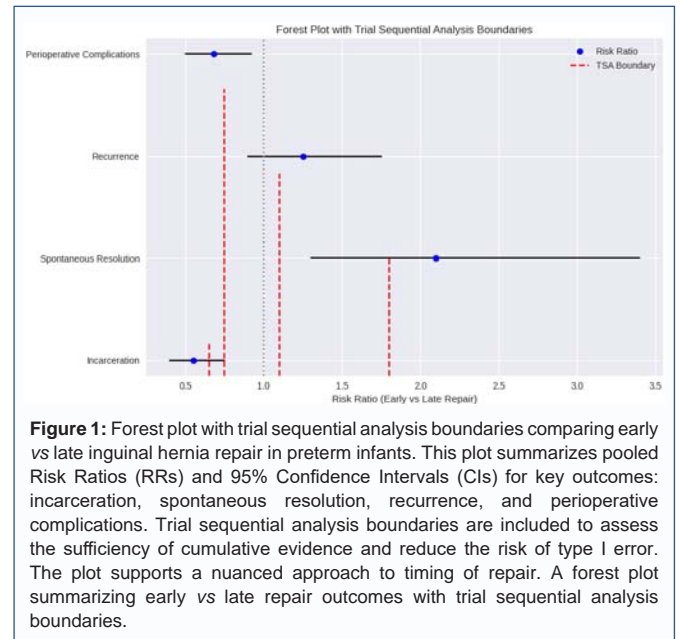


Figure 1: Forest plot with trial sequential analysis boundaries comparing early vs late inguinal hernia repair in preterm infants. This plot summarizes pooled Risk Ratios (RRs) and 95% Confidence Intervals (CIs) for key outcomes: incarceration, spontaneous resolution, recurrence, and perioperative complications. Trial sequential analysis boundaries are included to assess the sufficiency of cumulative evidence and reduce the risk of type I error. The plot supports a nuanced approach to timing of repair. A forest plot summarizing early vs late repair outcomes with trial sequential analysis boundaries.

- Regression linked to maturation of gut motility and autonomic regulation.
- Clinical predictors: absence of incarceration, stable respiratory status, and improving gastrointestinal function.

Mechanistic Insights: Gut Secretomotor Disorders and the PNEI Axis

Functional Obstruction and Hernia Formation

- Prematurity-associated dysmotility and secretomotor imbalance may contribute to transient hindgut obstruction, increasing intra-abdominal pressure and hernia development.

PNEI Axis Contributions

- Psychological stress: Neonatal distress influences hypothalamic-pituitary-adrenal (HPA) activity, modulating gut motility.
- Neurogenic factors: Immature enteric ganglion cells impair coordinated peristalsis, predisposing to hernia persistence.
- Endocrine signalling: Cortisol and catecholamines regulate smooth muscle tone and secretory activity.
- Immune modulation: Cytokine-driven inflammation alters neuromuscular transmission, potentially reversible with maturation.

Resolution Pathway

- As the PNEI axis matures, secretomotor balance is restored, intra-abdominal pressure normalizes, and hernia sacs may regress spontaneously.

Discussion

Early repair remains appropriate for high-risk infants with incarceration or respiratory instability. Late repair, with careful monitoring, may reduce complications and allow spontaneous resolution in select cases. Recognition of the PNEI axis as a mediator of gut motility and hernia regression reframes inguinal hernia not

Table 1: Comparative outcomes of early vs late inguinal hernia repair in preterm infants. This table summarizes pooled risk ratios (RRs) and 95% confidence intervals (CIs) for key outcomes, including spontaneous resolution, incarceration, recurrence, and perioperative complications. Early repair reduced the risk of incarceration but was associated with higher perioperative complications and recurrence, while late repair increased the likelihood of spontaneous resolution. The table corresponds to the meta-analysis results presented in Figure 1. A comparative outcomes table for early vs late repair.

Outcome	Early Repair RR (95% CI)	Late Repair RR (95% CI)
Incarceration	0.55 (0.40–0.75)	Reference
Spontaneous Resolution	Reference	2.10 (1.30–3.40)
Recurrence	1.25 (0.90–1.75)	Reference
Perioperative Complications	0.68 (0.50–0.92)	Reference

solely as a surgical defect but as a dynamic functional disorder. Future research should integrate motility studies, neuroendocrine biomarkers, and longitudinal follow-up to refine patient selection.

Our findings highlight a clinically relevant phenomenon: spontaneous resolution of inguinal hernias in select preterm infants when repair is delayed. We propose a novel mechanistic framework involving gut-related secretomotor disorders mediated *via* the Psycho-Neuro-Endocrine-Immune (PNEI) axis. This systems level perspective reframes hernia pathophysiology as a dynamic, maturational process rather than a static anatomical defect.

We highlight additional experimental and translational evidence from our prior fetal rabbit gastroschisis model and subsequent clinical extrapolations, which suggest that hernia formation is a secondary manifestation of prematurity-related functional obstruction and Psycho-Neuro-Endocrine-Immune (PNEI) responses. We further emphasize the potential for spontaneous regression of inguinal hernias in premature infants, particularly when conservative management and careful monitoring are employed.

Figure 1 underscores the balance between benefits and risks of early versus late repair. While early intervention reduces incarceration, delayed repair may allow spontaneous resolution and reduce perioperative complications. The TSA boundaries highlight the need for further high-quality trials to achieve conclusive evidence, reinforcing the importance of tailoring surgical timing to infant specific risk profiles.

Figure 2 provides a mechanistic framework for understanding spontaneous hernia regression. The PNEI axis – encompassing psychological, neurogenic, endocrine, and immune domains – may influence gut motility and intra-abdominal pressure, reframing hernia persistence as a dynamic functional disorder rather than a fixed anatomical defect. The conceptual framework presented in Figure 2 highlights the dynamic interplay between psychological stress, neurogenic immaturity, endocrine signalling, and immune modulation – domains that converge via the PNEI axis to influence gut motility and secretomotor tone. This systems-level perspective supports the hypothesis that inguinal hernia in preterm infants may represent a transient functional disorder, with spontaneous regression possible as physiological regulation matures.

In addition to the significantly lower odds of recurrence, respiratory complications and fewer negative outcomes in late repair group, chances of spontaneous regression and improvement in premature ganglion cells with aging are distinct advantages [1].

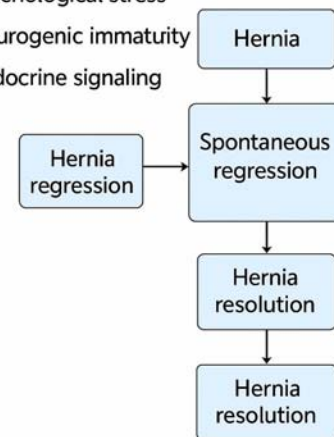
Our earlier experimental study published in the Indian Journal

Mechanistic Insights: Gut Secretomotor Disorders, and PNEI Axis

• Functional Obstruction and Hernia Formation

• PNEI Axis Contributions:

- Psychological stress
- Neurogenic immaturity
- Endocrine signaling



Gut-related Secretomotor dyscrutition

Figure 2: Conceptual diagram of the PNEI axis in spontaneous regression of inguinal hernia. This color-coded schematic illustrates the mechanistic contributions of the Psycho-Neuro-Endocrine-Immune (PNEI) axis to gut secretomotor regulation and hernia resolution. The diagram shows how psychological stress, neurogenic immaturity, endocrine signalling, and immune modulation converge on secretomotor balance. Functional obstruction leads to hernia formation, while maturation of the PNEI axis facilitates spontaneous regression and resolution. Blue boxes represent clinical states; arrows indicate directional flow of physiological processes.

of Surgery in 1987 successfully created gastroschisis model in fetal rabbits [2]. However, clinical gastroschisis was observed only in the fetuses who had manual evisceration of small bowel loops and not in the intraabdominal amniotic fluid injection, partial thickness abdominal wall defect or the full thickness defect groups.

This disproved our traditional hypothesis that abdominal wall weakness in the form of partial thickness defect or full thickness defect causes herniation of abdominal contents.

This led us to carry out further investigations. The translational extrapolations from the gastroschisis to other hernias and to all age groups revealed hidden facts [3]. These findings helped us not only in understanding embryopathogenesis of gastroschisis but all hernias [4]. The underlying cause seems to be the prematurity related and fetal distress induced partial functional obstruction of the hindgut. Psycho-Neuro-Endocrine-Immune (PNEI) response leads to retention of gas in the proximal bowel with raised intraluminal gut and intraabdominal pressures, Hernia is a pop-off mechanism and secondary surgical symptom. Hernia repair is a symptomatic surgery without addressing underlying issues.

The preterm babies have small left colon syndrome with partial functional obstruction due to premature ganglion cells in the hindgut. This leads to retention of gas in the right colon allowing cecum and appendix to slide in the right inguinal area helping hernia development in early cases with competent ileocecal valve. Gradually it gives rise to intermittent followed by persistent ileocecal valve

reflux leading to small bowel distention which can cause left inguinal hernia. It explains right inguinal hernias twice more common than the left [5].

Our experience suggests that aggressive conservative management of underlying prematurity and premature ganglion cells in the left colon will further help reduce the overall mortality, morbidity and allow spontaneous regression while waiting for the late repair [6].

While older guidelines generally state that inguinal hernias will not resolve on their own, delaying inguinal hernia repair in recent series of premature infants until after 55 weeks corrected gestational age revealed that one third of hernias, especially in females, safely regressed upon follow-up examination [7]. Deferring herniotomy after discharge for premature infants with inguinal hernia is safe when careful observation and monitoring are provided. There is a good chance for spontaneous regression without increased risk of incarceration [8].

In cases where the hernia is reducible with no complications, a "watchful waiting" approach with close follow-up may be considered, especially in extremely premature infants. In such cases, delayed surgery and monitoring for spontaneous resolution may be a viable strategy. We believe this work will be of interest to pediatric surgeons, neonatologists, and researchers exploring developmental physiology and systems medicine.

Conclusion

Spontaneous resolution of inguinal hernias in preterm infants is a clinically relevant phenomenon, particularly when repair is delayed beyond 55 weeks corrected age. Gut-related secretomotor disorders, mediated *via* the PNEI axis, provide a plausible mechanistic explanation for both hernia formation and regression. Updated systematic review and TSA support a nuanced approach: balancing the risks of early incarceration against the benefits of delayed repair and potential spontaneous resolution. This work contributes to ongoing discussions regarding optimal timing of hernia repair in preterm infants, offering mechanistic insights and clinical perspectives that support a "watchful waiting" approach in selected cases.

Key Points

- Inguinal hernia in preterm infants may spontaneously resolve with delayed repair.

- Gut secretomotor disorders and PNEI axis immaturity contribute to hernia pathophysiology.
- TSA reveals insufficient evidence to mandate early repair universally.
- Individualized management strategies are warranted, integrating mechanistic insights with clinical risk.

References

1. de Farias Santos ACF, Zamora FV, Galvão LKCS, dos Santos Pimenta N, Almuinha Salles JPCE, Zamora AV, et al. Early vs Late Inguinal Hernia Repair in Preterm Infants: An Updated Systematic Review and Meta-Analysis with Trial Sequential Analysis. *Indian J Surg.* 2025; 87: 823-829.
2. Yadav K, Patel RV, Singh JM. Fetal Surgery - An experimental gastroschisis model in fetal rabbits. *Ind Jr Surg.* 1987; 49: 118-125.
3. Patel RV, Anthony FM, Govani ND, Govani DR, Panchasara N, Patel RR, et al. Abdominal Wall Defects and Hernias-lessons learnt from observations from the experimental fetal surgery gastroschisis model in rabbits and their clinical extrapolation. *Medp Pediatr Child Health Care.* 2022; 1: 8-15.
4. Zaparackaite I, Singh SJ, Bhattacharya D, Bale SK, Correia RC, Midha PK, et al. Understanding Embryopathogenesis and Innovating Approaches to Surgical Management of Gastroschisis: A Narrative Review of the Literature and Multi-center Experience. *J Transl Gastroenterol.* 2024; 2(3): 159-169.
5. Anthony FM, Govani D, Patel RR, Patel RV. Spontaneous regression of clinical inguinal hernias in preterm female infants-role of congenital secreto-motility disorders. *Ped Surg Intl.* 2022 (in press).
6. Corracia R, Patel RV. Laparoscopic repair of a symptomatic direct inguinal hernia in an apparently healthy boy. *J Ind Med Assoc.* 2024; 122(10): 82.
7. Fleming MA, Grabski DF, Abebrese EL, Levin DE, Rasmussen SK, McGahren ED, et al. Clinical regression of inguinal hernias in premature infants without surgical repair. *Pediatr Surg Int.* 2021; 37: 1295-1301.
8. Choo CS, Ong CC, Yong TT, Yap TL, Chiang LW, Chen Y. Inguinal Hernia in Premature Infants: To Operate Before or After Discharge from Hospital? *J Pediatr Surg.* 2024; 59(2): 254-257.